



Data Article

Thyroid scan image dataset for the study of thyroid pathologies in adult patients

Benicio Grossling-Vallejos^{a,b}, Carolina E. Villegas Colmán^{a,b},
Ronald Rivas^a, María Gloria Pedrozo^a, Graciela Giménez^a,
Teresa Rojas^a, Marina Arnal^a, Nicole Barreto^a, Cynthia Duarte^a,
Andrés Uldera^a, Julio César Mello-Román^{b,*}, José Luis Vázquez
Noguera^b, Horacio Legal-Ayala^b, Edith Falcon de Legal^b

^a Universidad Nacional de Asunción, Instituto de Investigaciones en Ciencias de la Salud, San Lorenzo 111421, Paraguay

^b Universidad Nacional de Asunción, Facultad Politécnica, San Lorenzo 111421, Paraguay

ARTICLE INFO

Article history:

Received 19 October 2024

Revised 4 November 2024

Accepted 7 November 2024

Available online 13 November 2024

Dataset link: [Thyroid scan image dataset for the study of thyroid pathologies in adult patients \(Original data\)](#)

Keywords:

Dataset

Nuclear medicine

Thyroid scintigraphy

Thyroid pathologies

ABSTRACT

This article presents a dataset containing 641 images of Thyroid Gammagraphies studies corresponding to 235 patients over 18 years of age that were acquired in the period from 2016 to 2024 at the Nuclear Medicine Service of the *Instituto de Investigaciones en Ciencias de la Salud* of the *Universidad Nacional de Asunción* (IICS - UNA), Paraguay. First, the Thyroid Gammagraphies images were acquired according to the acquisition protocol described in this article. The thyroid scintigraphies images were acquired using trimodal SPECT-CT-PET equipment, model AnyScan SCP, MEDISO brand. The images were classified by the professionals of the Nuclear Medicine Service according to the diagnoses made by the nuclear physicians. They were grouped into toxic adenoma, diffuse goiter, multinodular goiter, nodular goiter, absent thyroid gland (total thyroidectomy), preserved thyroid gland, deformed thyroid gland, right hemithyroidectomy, autonomous nodule, hyperuptake nodule, hypouptake nodule, remnant after total thyroidectomy, iatrogenically blocked thyroid, De Quervain's subacute thyroiditis, and combined cases of diffuse or multinodular goiter with subacute thyroiditis. The

* Corresponding author.

E-mail address: juliomello@pol.una.py (J.C. Mello-Román).

generated dataset will be helpful for nuclear physicians and researchers working on classification algorithms for thyroid pathologies.

© 2024 The Author(s). Published by Elsevier Inc.

This is an open access article under the CC BY-NC license (<http://creativecommons.org/licenses/by-nc/4.0/>)

Specifications Table

Subject	Nuclear Medicine
Specific subject area	Thyroid scans
Data format	1. PNG (.png), Images of thyroid scans whose dimensions are 256 × 256. 2. Annotations of the classifications in an EXCEL file (.xlsx).
Type of data	• Image • Excel file
Data collection	Thyroid scintigraphy studies were acquired using a trimodal SPECT-CT-PET device, AnyScan SCP model from the MEDISO brand, under the following protocol: • Thyroid studies: Adult patients received an intravenous dose of 3–5 mCi of sodium pertechnetate (99mTc) solution. Image acquisition was performed with an energy window centered on the 140 keV photopeak of the spectrum, with a window width equal to 20 %. The acquisition matrix is 256 × 256 pixels. Images were acquired in the projections: Anterior, Left Anterior Oblique (LAO), and Right Anterior Oblique (RAO). LAO and RAO images are optional in the acquisition processes.
Data source location	The Thyroid scan image dataset for the study of thyroid pathologies in adult patients was acquired in the Nuclear Medicine Service of the Department of Biomedical Engineering and Imaging, <i>Instituto de Investigaciones en Ciencias de la Salud, Universidad Nacional de Asunción</i> , San Lorenzo 111421, Paraguay [1].
Data accessibility	Repository name: Thyroid scan image dataset for the study of thyroid pathologies in adult patients. Data identification number: 10.5281/zenodo.13900963 Direct URL to data: https://zenodo.org/records/13900964

1. Value of the Data

- This dataset is essential for Computer Science researchers as it enables them to develop computational models that facilitate the automatic diagnosis of thyroid pathologies. Its usefulness also extends to being an essential tool for evaluating and improving medical image processing algorithms.
- The dataset is invaluable to the medical community as it can be used as a crucial resource for training new professionals in Nuclear Medicine diagnosis.
- The dataset provided is essential in epidemiological research since it provides detailed information on the prevalence of thyroid pathologies in Paraguay. It not only contributes to the understanding of the burden of these diseases but also lays the foundation for more precise and personalized public health strategies.

2. Background

The thyroid is an endocrine gland in the lower neck, anterior to the trachea. It is responsible for the production and secretion of thyroid hormones and maintaining iodine homeostasis within the human body. The thyroid produces mainly the inactive thyroid hormone, or thyroxine (T4), and the active thyroid hormone, or triiodothyronine (T3), that regulate human metabolism. A thyroid disorder occurs when this gland hypersecretes or hyposecretes these hormones [2].

Thyroid pathologies are the most common diseases in the endocrine field and represent a challenge for public health in any country, as they lead to a significant decrease in people's quality of life, causing various ailments and, in their most serious forms, even death [3].

Goiter is an enlargement of the thyroid to compensate for inadequate hormone synthesis of the gland [3]. Recent studies indicate that among the most recurrent thyroid pathologies in Paraguay are goiter, which can be diffuse, nodular, or multinodular; thyroid nodules, which can be hyperuptake, hypouptake, or autonomous; thyroiditis; toxic adenoma; ectopic thyroid; and cases such as iatrogenically blocked thyroids and thyroids with preserved physiological characteristics [4].

3. Data Description

Unlike ultrasound and computed tomography (CT), which are used to identify thyroid nodules, 99m Tc thyroid scintigraphy is currently the primary method for assessing the position, shape, size, and functional status of the thyroid gland. Furthermore, it is essential in the treatment of various thyroid diseases [5,6].

The Nuclear Medicine Service of the IICS professionals has organized the dataset into 16 folders corresponding to diagnosed pathologies. Within each folder, the images were grouped again into 3 folders according to the projections used to acquire the images: Anterior, RAO, and LAO. This new data set includes 641 images for each type of projection, all related to diagnoses of thyroid pathologies obtained from thyroid scans. The labels of each image, along with its respective diagnosis, are detailed in the file Classification Annotations.xlsx.

Fig. 1 shows the information available in the XLSX file with the following description of each column:

- The 'Image' column contains the anonymized and renamed patient image number.
- The 'Format' column indicates the image format (PNG).
- The "Age" column specifies the age of the patient.
- The "Sex" column specifies the sex of the patient.
- The "Weight" column specifies the patient's weight.
- The "Height" column specifies the height of the patient.
- The "Dose Administered" column specifies the radiopharmaceutical dose administered to the patient.
- The "Diagnosis" column specifies the type of pathology diagnosed.
- The "Oblique" column indicates whether said acquisition has RAO and LAO oblique images.

Fig. 2 shows that the prevalence of thyroid disease is higher in the female population, which represents 92.3 % (217 patients) of the total number of patients. However, the male population represents 7.7 % (18 patients). This distribution pattern suggests a trend consistent with prior studies on thyroid pathologies, where a higher incidence is observed in females [7].

Fig. 3 shows the patients' age distribution. The minimum age for the female population is 18, while for the male population, it is 22. The mean age is 49 for females and 51 for males. The maximum age is 86 for the female population and 78 for the male population.

Table 1 shows the classification of the database and the number of thyroid scintigraphy images for each category.

Fig. 4 shows images of the different thyroid pathologies in the anterior projection.

4. Experimental Design, Materials and Methods

The acquisition of 641 thyroid scan images from patients over 18 years of age was carried out using a standardized acquisition protocol at the Nuclear Medicine Service of the Instituto de Investigaciones en Ciencias de la Salud (IICS-UNA) between 2016 and 2024. The protocol is described below

	A	B	C	D	E	F	G	H	I
	IMAGE	FORMAT	AGE	SEX	WEIGHT (Kg)	HEIGHT (cm)	DOSE ADMINISTERED (mCi)	DIAGNOSIS	OBLIQUE
1									
2	1	PNG	49	FEMALE	75	175	3,0	TOXIC ADENOMA	NO
3	2	PNG	44	FEMALE	107	158	4,0	DIFFUSE GOITER	YES
76	75	PNG	31	FEMALE	58	159	4,2	DIFFUSE GOITER	YES
77	76	PNG	74	FEMALE	71	158	4,3	DIFFUSE GOITER, DE-QUERVAIN'S SUB-ACUTE THYROIDITIS	NO
78	77	PNG	65	FEMALE	95	160	4,2	DIFFUSE GOITER, DE-QUERVAIN'S SUB-ACUTE THYROIDITIS	YES
79	78	PNG	53	FEMALE	72	160	4,0	MULTINODULAR GOITER	YES
182	181	PNG	57	FEMALE	90	167	5,0	MULTINODULAR GOITER	YES
183	182	PNG	37	FEMALE	80	171	4,5	MULTINODULAR GOITER, DE-QUERVAIN'S SUB-ACUTE THYROIDITIS	YES
184	183	PNG	31	FEMALE	74	170	4,4	MULTINODULAR GOITER, DE-QUERVAIN'S SUB-ACUTE THYROIDITIS	YES
185	184	PNG	45	FEMALE	102	165	4,2	NODULAR GOITER	YES
198	197	PNG	28	FEMALE	87	166	5,0	NODULAR GOITER	YES
199	198	PNG	43	FEMALE	70	159	4,4	ABSENT THYROID GLAND - TOTAL THYROIDECTOMY	NO
200	199	PNG	51	FEMALE	64	164	4,9	PRESERVED THYROID GLAND	YES
207	206	PNG	29	FEMALE	62	158	5,0	PRESERVED THYROID GLAND	YES
208	207	PNG	76	FEMALE	48	150	4,5	DEFORMED THYROID GLAND	YES
209	208	PNG	22	MALE	75	180	4,8	RIGHT HEMITHYROIDECTOMY	YES
210	209	PNG	67	FEMALE	40	163	3,8	AUTONOMOUS NODULE	YES
218	217	PNG	59	FEMALE	67	165	5,0	AUTONOMOUS NODULE	YES
219	218	PNG	70	FEMALE	68	148	3,3	HYPERUPTAKE NODULE	YES
224	223	PNG	64	FEMALE	95	160	4,6	HYPERUPTAKE NODULE	YES
225	224	PNG	56	FEMALE	64	162	5,0	HYPOUPTAKE NODULE	NO
226	225	PNG	45	FEMALE	93	166	5,0	HYPOUPTAKE NODULE	YES
227	226	PNG	58	FEMALE	61	155	5,0	REMNANT AFTER TOTAL THYROIDECTOMY	YES
228	227	PNG	61	FEMALE	53	162	4,8	IATROGENICALLY BLOCKED THYROID	YES
230	229	PNG	69	FEMALE	97	155	4,0	IATROGENICALLY BLOCKED THYROID	NO
231	230	PNG	64	FEMALE	56	149	4,3	DE-QUERVAIN SUB-ACUTE THYROIDITIS	NO
236	235	PNG	18	FEMALE	48	152	5,0	DE-QUERVAIN SUB-ACUTE THYROIDITIS	YES

Fig. 1. Example of fields and data structure in the annotation XLSX file. This table provides a quick and structured reference for analyzing each image and its medical classification.

Table 1

Number of thyroid scintigraphy images in anterior projection by pathology.

Diagnosis	Number of images
Toxic adenoma	1
Diffuse goiter	74
Diffuse goiter, De-Quervain's sub-acute thyroiditis	2
Multinodular goiter	104
Multinodular goiter, De-Quervain's sub-acute thyroiditis	2
Nodular Goiter	14
Absent thyroid gland - Total thyroidectomy	1
Preserved thyroid gland	8
Deformed thyroid gland	1
Right hemithyroidectomy	1
Autonomous Node	9
Hyperuptake nodule	6
Hypouptake nodule	2
Remnant after total thyroidectomy	1
Iatrogenically blocked thyroid	3
De-Quervain sub-acute thyroiditis	6

GENDER DISTRIBUTION OF PATIENTS

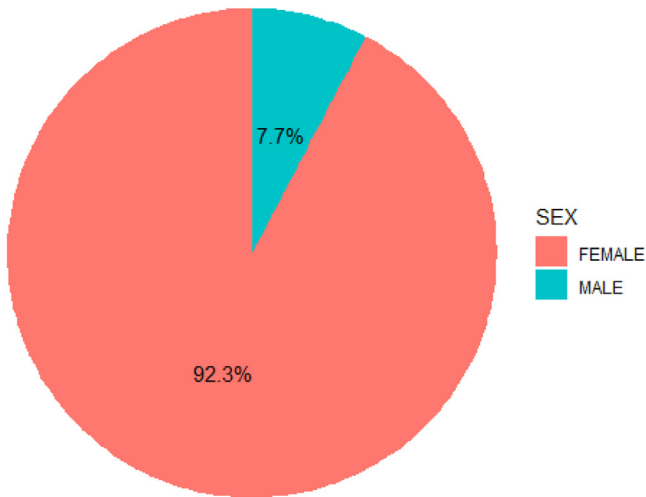


Fig. 2. Gender distribution of patients in the dataset. The prevalence of thyroid diseases is higher in females, accounting for 92.3 % (217 patients), while males represent 7.7 % (18 patients).

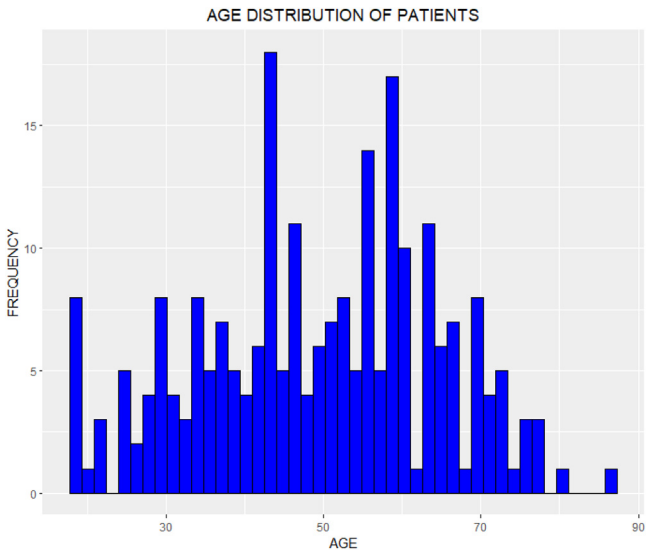


Fig. 3. The age distribution of patients shows the age variability in the study population, with a higher concentration in middle and advanced age groups.

1. Patients are interviewed, their data are recorded in a patient file, and informed consent is obtained.
2. A dose of ^{99m}Tc radiopharmaceutical with an activity between 3 and 5 mCi is administered intravenously. The examination begins 15 minutes after the radiopharmaceutical is injected.

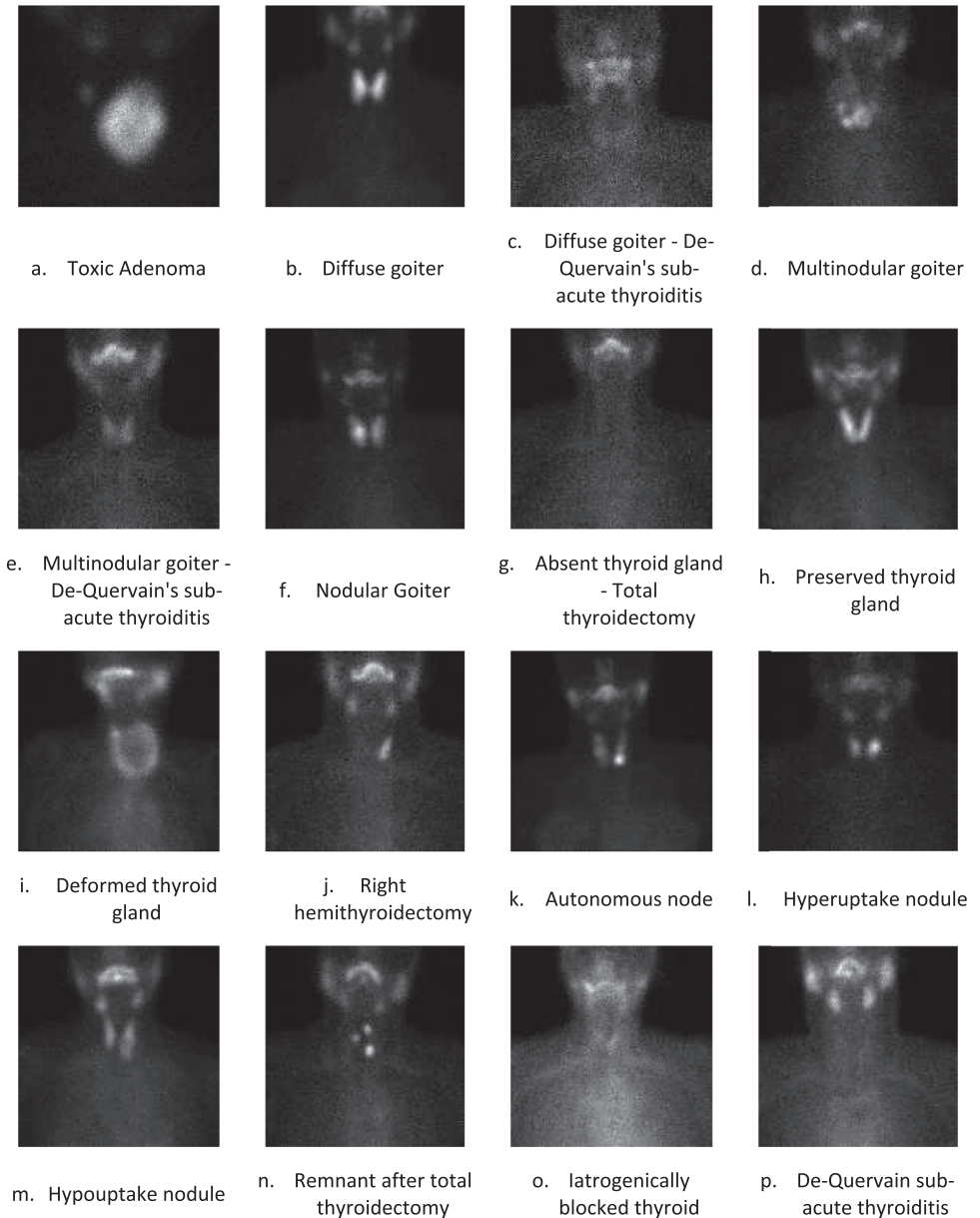


Fig. 4. Examples of images showing various thyroid pathologies are captured in the anterior projection. These images illustrate the diversity of thyroid presentations that can be analyzed via scintigraphy.

3. Instrumentation: The study was acquired using a MEDISO brand trimodal SPECT-CT-PET dual-head gamma camera, model AnyScan SCP¹.

4. First acquisition: Anterior Planar.

¹ Mediso Medical Imaging Systems, **AnyScan® Family** - **AnyScan®**, Mediso. Available at: <https://mediso.com/global/en/product/anyscanr-family/anyscanr>.

- Patient preparation: Urination prior to acquisitions. Metal objects are removed from the area under study.
 - Exploration type: Static.
 - Patient orientation: Supine position/head in, neck in hyperextension.
 - Collimator: LEHR.
 - Energy window: ± 20 % centered at 140 keV.
 - Image matrix: 256×256 pixels.
 - Duration (minutes/ kcts): Maximum time of 5 minutes. Accounts (Kcts): 400 - 500.
 - Image representation: Grayscale.
5. Second acquisition (Optional): Planar Anterior obliques. Left Anterior Oblique (LAO) and Right Anterior Oblique (RAO)
- The preparation and parameters are the same as previously described.
 - Gantry Angle 135° for LAO and 225° for RAO.
 - Prosecution
 - The anterior planar image is processed using the MEDISO InterView™ XP software. The regions of interest in the thyroid and nodules are outlined to determine parameters for medical diagnosis.

Ethics Statement

For the publication of this work, the approval of the manuscript entitled *Thyroid scan image dataset for the study of thyroid pathologies in adult patients* was obtained from the Research Ethics Committee of the Instituto de Investigaciones en Ciencias de la Salud of the Universidad Nacional de Asunción, with code M06/2024. The images were selected from the Nuclear Medicine Service patient database, from patients who signed the informed consent form. Their personal data remain anonymous, and their pathological conditions are treated with full confidentiality. The head of the Department of Biomedical Engineering and Imaging authorized the use of data from the Nuclear Medicine Service.

Credit Author Statement

Benicio Grossling: Conceptualization, Research, Resources, Data Curation, Writing - original draft, Visualization; **Carolina E. Villegas Colmán:** Conceptualization, Research, Resources, Data Curation, Writing - original draft, Visualization; **Ronald Rivas:** Data Curation, Research, Visualization; **María Gloria Pedrozo:** Data Curation, Research, Visualization; **Graciela Giménez:** Data Curation, Research, Visualization; **Teresa Rojas:** Data Curation, Research, Visualization; **Marina Arnal:** Data Curation, Research, Visualization; **Nicole Barreto:** Data Curation, Research, Visualization; **Cynthia Duarte:** Data Curation, Research, Visualization, **Andrés Uldera:** Data Curation, Research, Visualization; **Julio Cesar Mello-Román:** Validation, Writing - review and editing; **José Luis Vázquez Noguera:** Validation, Writing - review and editing; **Horacio Legal-Ayala:** Validation, Writing - review and editing; **Edith Falcon:** Validation, Writing - review and editing.

Data Availability

Thyroid scan image dataset for the study of thyroid pathologies in adult patients (Original data) (Zenodo).

Acknowledgments

The research project [INIC01-284](#) is co-funded by CONACYT, Paraguay with the support of FEEI.

Declaration of Competing Interest

The authors declare that they have no known competing financial interests or personal relationships that could have influenced the work presented in this article.

References

- [1] B. Grossling-Vallejos, et al., Thyroid scan image dataset for the study of thyroid pathologies in adult patients, Zenodo (2024), doi:[10.5281/zenodo.13900964](https://doi.org/10.5281/zenodo.13900964).
- [2] y S. Melmed, R. Koenig, C.J. Rosen, R.J. Auchus, A.B. Goldfine, *Williams Textbook of Endocrinology*, 14th ed Elsevier, Nueva York, NY, 2020.
- [3] L. Aversano, M.L. Bernardi, M. Cimitile, A. Maiellaro, R. Pecori, A systematic review on artificial intelligence techniques for detecting thyroid diseases, *PeerJ Comput. Sci.* 9 (2023) e1394, doi:[10.7717/peerj-cs.1394](https://doi.org/10.7717/peerj-cs.1394).
- [4] M. Pedrozo, G. Giménez, T. Rojas, B. Grossling, J. Núñez, P. Galván, Determination of the functional characteristics of thyroid nodules through nuclear medicine images in patients, who attended the Instituto de Investigaciones en Ciencias de la Salud - UNA, in the period 2016–2019, *Rev. Públ. Paraguay* 10 (1) (2020) 59–65, doi:[10.18004/rspp.2020.enero.59-65](https://doi.org/10.18004/rspp.2020.enero.59-65).
- [5] T. Qiao, et al., Deep learning for intelligent diagnosis in thyroid scintigraphy, *J. Int. Med. Res.* 49 (1) (2021), doi:[10.1177/0300060520982842](https://doi.org/10.1177/0300060520982842).
- [6] H. Zhao, et al., Diagnosis of thyroid disease using deep convolutional neural network models applied to thyroid scintigraphy images: a multicenter study, *Front. Endocrinol.* 14 (2023), doi:[10.3389/fendo.2023.1224191](https://doi.org/10.3389/fendo.2023.1224191).
- [7] M.P.J. Vanderpump, The epidemiology of thyroid disease, *Br. Med. Bull.* 99 (1) (2011) 39–51, doi:[10.1093/bmb/ldr030](https://doi.org/10.1093/bmb/ldr030).